

Full Regression of Peyronie's Disease Plaque Following Combined Antioxidant Treatment: A Three-Case Report.

Peyronie's disease (PD) is a fibrotic disorder of the tunica albuginea of the penis. Conservative medical therapy includes oral and/or injective active substances. Until now, only two PD patients who recovered after medical treatment are described in the literature. This article describes three new cases of PD patients who achieved complete resorption of plaque following antioxidant treatment. Case Presentations: Case 1. The patient was a 34-year-old man, a smoker, with lateral-left penile curvature (40 degrees), penile pain, and good penile rigidity. The patient was treated with combined therapy (oral antioxidants + Propolis creme). At follow-up, after about 29 months of treatment, we observed the disappearance of the acquired penile deformity. The ultrasound examination no longer showed any plaque. Case 2. The patient was a 32-year-old man with chronic prostatitis, penile lichen sclerosus, lateral-left penile curvature (10 degrees), a palpable lump, and good penile rigidity. The patient was treated with combined therapy (oral antioxidants + Propolis creme + penile injections of pentoxifylline). After 33 months of treatment, at follow-up, we observed the disappearance of the penile deformity. Ultrasound examinations no longer showed any plaque. Case 3. The patient was a 33-year-old man with penile pain, dorsal penile curvature (30 degrees), and good penile rigidity. The patient was treated with combined therapy (oral antioxidants + Propolis creme + penile injections of pentoxifylline). At follow-up, after 41 months of treatment, the penile pain was no longer present, and the ultrasound study no longer showed any plaque. Conclusions: Although our study presents a limited number of cases, it is a matter of fact that these patients obtained full regression in the affected area. We believe our experience may be very useful for urological clinical practice.

Gianni Paulis, Giovanni De Giorgio

Figures

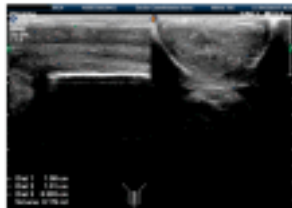


Figure 1

Ultrasonography of the penis before...

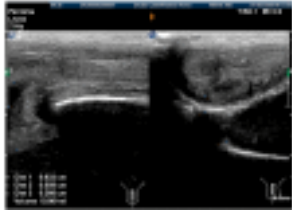


Figure 2

Ultrasonography of the penis after...

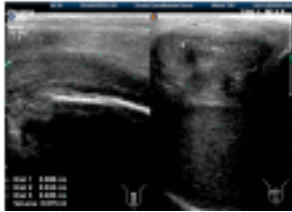

Figure 3

Ultrasonography of the penis after...

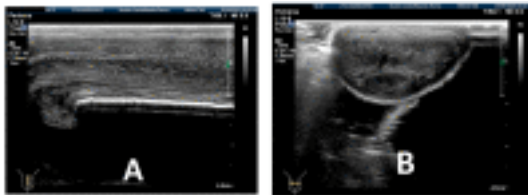


Figure 4

Ultrasonography of the penis after...

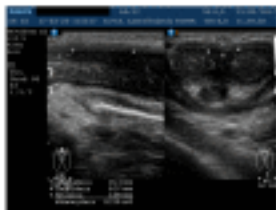


Figure 5

Ultrasonography of the penis before...

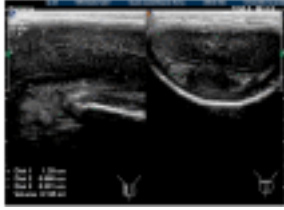


Figure 6

Ultrasonography of the penis after...

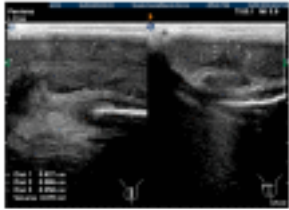


Figure 7

Ultrasonography of the penis after...

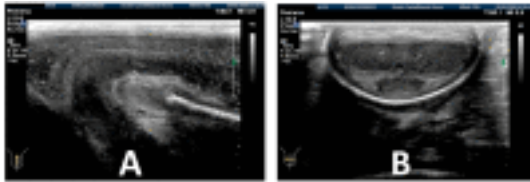


Figure 8

Ultrasonography of the penis after...

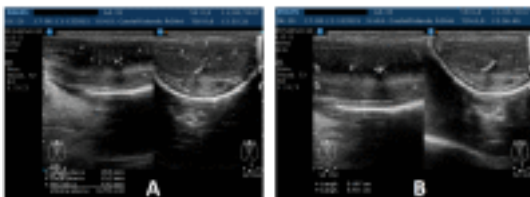


Figure 9

Ultrasonography of the penis before...

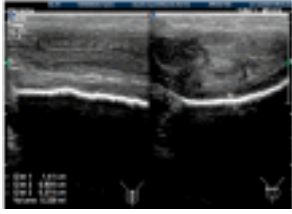


Figure 10

Ultrasonography of the penis after...

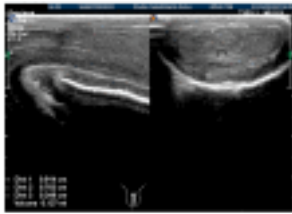


Figure 11

Ultrasonography of the penis after...

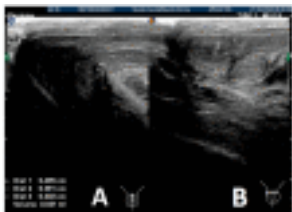


Figure 12

Ultrasonography of the penis after...

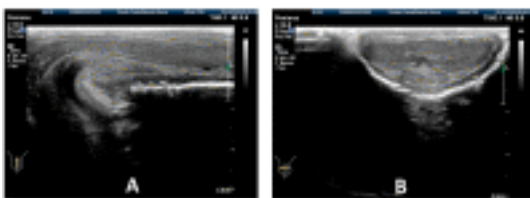


Figure 13

Ultrasonography of the penis after...

PubMed <http://www.ncbi.nlm.nih.gov/pubmed/36139736>

Keywords: Peyronie's disease; antioxidants; oxidative stress.